

# LANGERHANS CELL HISTIOCYTOSIS SINGLE SYSTEM MULTIFOCAL BONE INVOLVEMENT

## A CASE REPORT WITH REVIEW OF THE LITERATURE

By

Sarah M. Alfaqaih<sup>1,2</sup>, Alya S. Elshahoubi<sup>2</sup>, Fatima A. Eltawahny<sup>2</sup>

1- Department of pediatrics, Faculty of Medicine, University of Misurata, Misurata-Libya.

2- Department of pediatric oncology, National Cancer Institute, Misurata, Libya.

---

### ABSTRACT

Langerhans cell histiocytosis is a rare disease with abnormal accumulations of Langerhans cells in different body organs. The skeletal system is a commonly the affected site in pediatric populations, and treatment modalities are varied according to the affected sites and the extent of the disease. We present the clinical details of a 12-year-old girl patient diagnosed with single-system multifocal skeletal involvement (SS-LCH). The scans of her spine revealed a full collapse fracture of the seventh thoracic vertebral body, along with other lytic lesions affecting the vertebrae at levels D2, D5, and L1. The patient had chemotherapeutic treatment in accordance with the established guidelines for Langerhans cell histiocytosis. The radiographic features alone may evoke a higher level of suspicion for Langerhans cell histiocytosis (LCH), but they lack sufficient diagnostic capacity on their own. Histopathological examinations are necessary to definitively establish or rule out a diagnosis of Langerhans cell histiocytosis (LCH). Prompt medical intervention is necessary in order to halt the advancement of the disease and mitigate the need for more intrusive therapeutic measures.

**KEYWORDS:** Langerhans cells histiocytosis, LCH, skeletal, multifocal.

---

### INTRODUCTION

Langerhans cell histiocytosis (LCH) is a rare disorder characterized by abnormal neoplastic proliferation of the dendritic cell of myeloid origin that is driven by mutations in the mitogen-activated protein kinase pathway [1-3]. The identification of oncogenic BRAF or MAP2K1 mutations in most cases of LCH suggests that it is a clonal neoplasm [4,5]. Krooks et al, initiate the development of diagnostic criteria aimed at facilitating early and accurate diagnosis and treatment of LCH [6].

LCH has a clinical presentation that has the potential to overlap with several other medical conditions, such as cutaneous metastasis, particularly in cases of leukemia, neuroblastoma, and rhabdomyosarcoma [7]. Additionally, LCH may have similarities with seborrheic dermatitis, psoriasis, and atopic dermatitis. The acquisition of a biopsy specimen is essential in order to establish a diagnosis of LCH [8]. However, it is important to note that the presence of Langerhans cell reactivity alone is not sufficient to confirm a diagnosis of LCH. Instead, the diagnosis should be made in consideration of the relevant clinical

---

Corresponding author: Sarah M. Alfaqaih  
Email: [sarah.alfaqaih@med.misuratau.edu.ly](mailto:sarah.alfaqaih@med.misuratau.edu.ly)

context. Immunohistochemistry staining for CD1a / S100 antigens is needed for the diagnosis of LCH [2,9]. Bone marrow aspiration and biopsy specimens are recommended for individuals who are suspected of having multisystem illness and present with cytopenia. The purpose of these procedures is to investigate and eliminate other potential causes of bone marrow failure, such as leukemia [6].

LCH is considered a sporadic disease despite a literature report of possible genetic predisposition, predominantly reported in younger age groups with an estimated annual incidence of 6–8 cases per million children in comparison to 1–2 cases per million reported for the adult age group [10,11]. All body organs are at risk of clonal infiltration of LCH, with skeletal predominance at 65–80% [12–14]. The risk stratification of LCH ranges from a single system-affected LCH (SS-LCH) with unifocal or multifocal bony lesions to a multisystem LCH (MS-LCH) [14]. All bones could be affected by LCH, although the skull, ribs, and pelvis are commonly involved [15]. Single-system unifocal skeletal involvement is the predominant presentation of cases previously reported [16].

The treatment, outcome, and follow-up protocol of bone involvement in LCH have multiple varieties from one place to another. The protocols range from conservative measures for single lesions to chemotherapy and radiotherapy for selected scenarios [16,17]. For disorders that are resistant to vinblastine, prednisone, or salvage therapy, hematopoietic stem cell transplantation provides an additional efficacious therapeutic alternative [18].

We report this unusual presentation of spinal LCH with compressed fractures of vertebrae and multiple lytic spinal lesions on the imaging study.

The protocol of treatment was approved by the local institutional committee review board at the national cancer institute in Misurata, Libya (No. 06/2023). The parents declare consent for the publication of their child's data.

### Case report

A 12-year-old female, previously healthy, presented with back pain that evolved over 7 months. She was evaluated initially, had no laboratory abnormalities, and was treated with an oral analgesic. She comments that the pain increased in severity over time and radiated to the lower extremities. Afterward, she was evaluated by imaging studies (CT and MRI). Examinations of the spine showed a complete collapse fracture of the seventh thoracic vertebral body with other lytic lesions involving the spine (D2, D5, and L1).

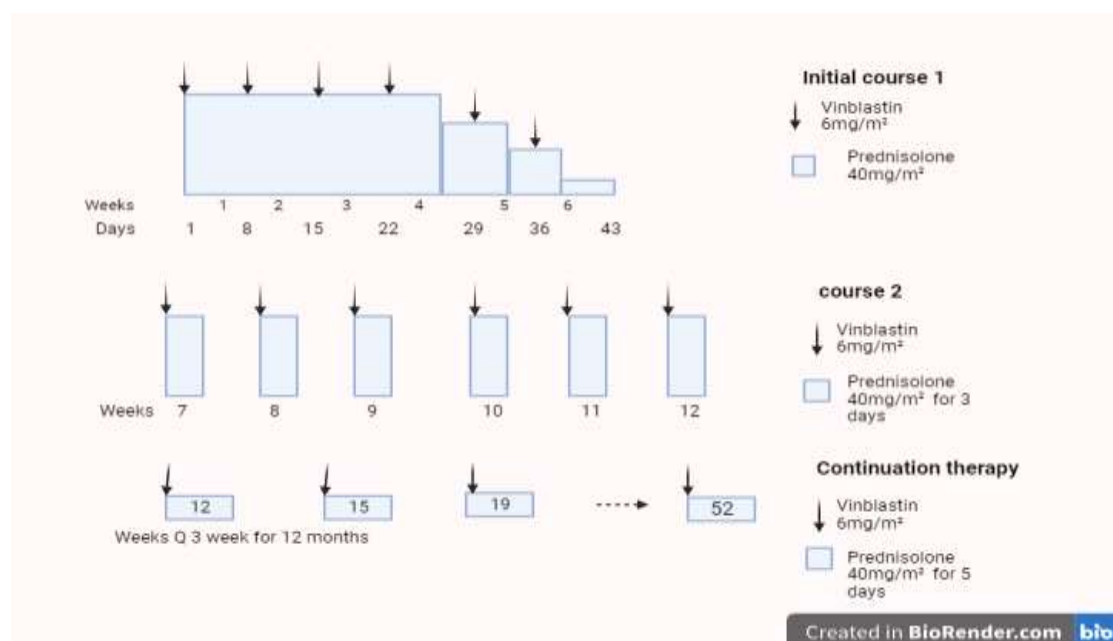
She underwent internal fixation of a vertebral fracture, and a biopsy was performed. Histologic examination of biopsied tissues showed diffuse infiltration of small lymphocytes admixed with ovoid histiocytic cells with eosinophilic cytoplasm, some of which have grooved nuclei.

Immunohistochemical staining showed diffusely positive S100 for Langerhans cells, which consists of the diagnosis of LCH.

Postoperatively and after the diagnosis of LCH has been established, involvement of other organs and disease staging according to the clinical, laboratory, and radiologic criteria have been made (Table 1)[14]. To highlight in this case, comparative

radiologic survey results between initial imaging and a postoperative radiologic skeletal survey showed a progressive course of LCH at the level of the skull bone (parietal and frontal bone) over a period of about 4 months. She has single-system (bone) involvement with a multifocal lesion (SS-LCH multifocal) and no special sites or risk organs affected.bb . This patient received chemotherapy protocol according to Langerhans cell histiocytosis guidelines [14,19]. She received a total duration of 12 months. She conducted initial treatment course 1 for 6 weeks duration including prednisolone (PRED) 40mg/m<sup>2</sup>/day orally, weekly reduction after week 4, and Vinblastine (VBL) 6mg/m<sup>2</sup> i.v bolus weekly). She has been evaluated for response post initial course1 and revealed a static disease course. Then she proceeded to course 2 of initial treatment from week 7 to week 12 includes (PRED 40mg/m<sup>2</sup>/day orally,

weekly for 3 days, and VBL 6mg/m<sup>2</sup> i.v bolus weekly), (Figure 1). Re-evaluation of the response by radiographic skeletal survey confirms a complete response off therapy for initial courses of treatment in favor of the absence of previously seen lytic lesions of vertebrae and skull bones. According to treatment guidelines, she proceeds with continuation treatment to complete 52 weeks of protocol that includes (PRED 40mg/m<sup>2</sup>/day orally for 5 days Q 3 weeks and VBL 6mg/m<sup>2</sup> i.v bolus Q 3 weeks). We do not observe significant side effects throughout the treatment course. The end-of-treatment evaluation showed a complete response and close follow-up was advised every six weeks, 12 weeks for clinical and laboratory evaluation respectively. The reported case followed closely and last follow-up at 23 months post off-therapy and has no signs of disease relapse.



**Figure (1):** The Histiocyte Society protocol of treatments, “Created with [BioRender.com](https://www.biorender.com).”

## Discussion

This report focuses on the multifocal bone-single system affected by LCH. LCH is mostly reported in the first and second decade (between 5 and 20 years of age)[20]. The skeletal system affected by LCH typically involves flat bone, particularly the craniofacial region in pediatric and adult age groups [12, 21-23], **Table 2**, shown the literatures review of variety of presentation and modules of treatments. Imasuku et al.[21], reported that skull bones are mostly affected followed by the spine then lower extremities and there is no significant reporting about literality. LCH-spine, Abdelaal et al.[12], was involved in 15 patients (8.1%). The dorsal vertebrae were the most commonly affected (8 cases), followed by the cervical spine in (5 cases) and the lumbar spine in (4 cases). Whenever bone LCH is confirmed, it is crucial to determine either single system, multisystem, focal bone, multifocal bone or involves "risk" bone:(lesions in the orbital, temporal, mastoid, sphenoidal, zygomatic, or ethmoidal bones; the maxilla or paranasal sinuses; or cranial fossa; with intracranial soft tissue extension)[14].

The clinical presentation of LCH varies from pain, pathological fracture, painless deformity, and swelling [17, 21, 22, 24]. Vadivelu, et al and Buonocore, et al.[24, 25], they present (case 1), 11-month-old; (case 2), three-years-old, complains of lower limb weakness and reported to have multiple spine lytic lesions with collapsed (T3), (T6, L4) vertebrae respectively. Our reported case presented with back pain of long duration and kyphosis later on, which was confirmed by an imaging study of a compressed fracture of thoracic vertebrae that required surgical intervention. The various options of treatment have been conducted for

LCH including observation, oral indomethacin, corticosteroid, excisional biopsy, bone grafting, immobilization, radiofrequency ablation, and chemotherapy. According to the disease burden treatment line is crucial to select. However, in multifocal bone-LCH and isolated-LCH of critical anatomic sites, treatment with systemic chemotherapy may have resulted in a lower incidence of reactivation and minimized morbidity [22, 26].

Several protocols have been conducted over the last 20 years. However, combined prednisolone(PRED) and Vinblastine(Vinbl) were recommended by LCH society for MFB-SS-LCH without risk of bone affected[19]. PRED/Vinbl are commonly reported by literature with significant responses achieved [14, 21, 22, 27]. Abdelaal et al. [12], only observation and follow-up for the affected patient were reported. They were immobilization, fixation of critical anatomic sites (vertebrae compressed fracture), biopsies, and indomethacin. The result of to mean time to partial bone remolding was 2.3 months. The mean follow-up duration was 53.3 months (0.2 m– 120.7 m). on the other hands, the disease progression and reactivation that occurred within two years from initial diagnosis have been reported[22]. Our mentioned case was presented earlier with multifocal spinal lytic lesions which progressed over four month's period before initiation of treatment. Therefore, as a consequence of delayed diagnosis, disease progression or reactivation for MFB-SS permanent consequences mush higher documented. The number of bone lesions has a significant correlation with reported sequel[22]. The literature review of single system multifocal skeletal involvements were reported by:- (1) Abdelaal, et al. [17], they reported 65 cases, there age

ranged from 0.48-12.36 years ( $4.27\pm 3$ ), presenting symptoms were pain and fracture deformity, the involved skeletal site were craniofacial 5 cases, spine 15 cases, pelvis 15 cases, tibia 3 cases, shoulder girdle 6 cases, forearm 2 cases and femur 19 cases. (2) Vadivelu, et al [25], they reported one case, 13 months age, presenting symptom was lower extremity weakness, the involved skeletal site was multiple spine lytic lesion with collapsed T3 vertebrae with compressed mass. (3) Imashuku, et al. [21], they reported 67 cases, the involved skeletal site were, skull 65 cases, facial bone 8 case, spine 41 cases, upper torso 23 cases pelvis 22 cases, femur head 4 cases, femur 9 cases, tibia 2 cases, fibula 1 case and not specified 2 cases. (4) Buonocore, et al. [24] they reported one case, 3 years old, presenting symptom was pain, the involved skeletal site were multiple spine lytic lesion with collapsed T6, L4 vertebral bodies and compressed soft tissue mass. (5) Titgemeyer, et al.[22], they reported 34 cases, there age ranged from 10 months -17.1 years ( $7.27\pm 12.5$ ), the presenting symptoms were pain and swelling, the involved skeletal site were skull, spine and long bones.

### CONCLUSION

While the LCH is a rather uncommon condition, it should be taken into consideration as a potential component of the differential diagnosis. The radiologic imaging characteristics in isolation may elicit a greater degree of suspicion for Langerhans cell histiocytosis (LCH), but they do not possess enough diagnostic capability alone. Histopathological investigations are required in order to confirm or exclude a diagnosis of Langerhans cell histiocytosis (LCH). There is currently no generally recognized standard of care for the treatment of Langerhans

cell histiocytosis (LCH). Nevertheless, the therapeutic approach should be tailored to each patient, taking into consideration their specific clinical characteristics such as neurologic impairment, the anatomical site of the disease, and the level of involvement that is demonstrated by radiographic scanning. Multifocal bone LCH without "risk" bone involvement an effective early systemic therapy could be beneficial and prevent disease burden.

### REFERENCES

1. Bedran NRC, R.: de Andrade, B. A. B.: Bueno, A. P. S.: Romañach, M. J.: Milito, C. B.: Clinicopathological and Immunohistochemical Study of Head and Neck Langerhans Cell Histiocytosis from Latin America. *Head and neck pathology* 2018, 12(4):431-439.
2. Hashimoto KN, S.: Sakata, N.: Inoue, M.: Sawada, A.: Akagi, M.: Treatment Outcomes of Langerhans Cell Histiocytosis: A Retrospective Study. *Medicina (Kaunas, Lithuania)* 2021, 57(4).
3. Emile JF, Abla O, Fraitag S, Horne A, Haroche J, Donadieu J, Requena-Caballero L, Jordan MB, Abdel-Wahab O, Allen CE et al: Revised classification of histiocytoses and neoplasms of the macrophage-dendritic cell lineages. *Blood* 2016, 127(22):2672-2681.
4. Christopher Z, Binitie O, Henderson-Jackson E, Perno J, Makanji RJ: Langerhans cell histiocytosis of bone in an adult: A case report. *Radiol Case Rep* 2018, 13(2):310-314.
5. Kálmán J, Horváth T, Liktor B, Liktor B: A unique manifestation of Langerhans cell histiocytosis: Diagnostic and therapeutic considerations of atypical cases. *Ear Nose Throat J* 2018, 97(4-5):E13-e17.

- 6.Krooks J, Minkov M, Weatherall AG: Langerhans cell histiocytosis in children: Diagnosis, differential diagnosis, treatment, sequelae, and standardized follow-up. *J Am Acad Dermatol* 2018, 78(6):1047-1056.
- 7.Kim BE, Koh KN, Suh JK, Im HJ, Song JS, Lee JW, Kang HJ, Park KD, Shin HY, Choi HS et al: Clinical features and treatment outcomes of Langerhans cell histiocytosis: a nationwide survey from Korea histiocytosis working party. *J Pediatr Hematol Oncol* 2014, 36(2):125-133.
- 8.Board PDQPTC: Langerhans Cell Histiocytosis Treatment (PDQ®): Health Professional Version. In: *PDQ Cancer Information Summaries*. Bethesda (MD): National Cancer Institute (US); 2002.
- 9.Kim BEK et al.: Clinical features and treatment outcomes of Langerhans cell histiocytosis: a nationwide survey from Korea histiocytosis working party. *Journal of pediatric hematology/oncology* 2014, 36(2):125-133.
- 10.Alston RDT, R. G.: McNally, R. J.: Kelsey, A.: Birch, J. M.: Eden, T. O.: Incidence and survival of childhood Langerhans cell histiocytosis in Northwest England from 1954 to 1998. *Pediatric blood & cancer* 2007, 48(5):555-560.
- 11.Guyot-Goubin AD, J.: Barkaoui, M.: Bellec, S.: Thomas, C.: Clavel, J.: Descriptive epidemiology of childhood Langerhans cell histiocytosis in France, 2000-2004. *Pediatric blood & cancer* 2008, 51(1):71-75.
- 12.Abdelaal AHKS, M.: Gohar, S.: Zaki, I.: Salama, A.: Hassanain, O.: El Ghoneimy, A. M.: Skeletal involvement in children with Langerhans cell histiocytosis: healing, complications, and functional outcome. *SICOT J* 2020, 6:28.
- 13.El Demellawy DY, J. L.: de Nanassy, J.: Chernetsova, E.: Nasr, A.: Langerhans cell histiocytosis: a comprehensive review. *Pathology* 2015, 47(4):294-301.
- 14.Haupt R, Minkov M, Astigarraga I, Schafer E, Nanduri V, Jubran R, Egeler RM, Janka G, Micic D, Rodriguez-Galindo C et al: Langerhans cell histiocytosis (LCH): guidelines for diagnosis, clinical work-up, and treatment for patients till the age of 18 years. *Pediatric blood & cancer* 2013, 60(2):175-184.
- 15.Khung S, Budzik JF, Amzallag-Bellenger E, Lambilliotte A, Soto Ares G, Cotten A, Boutry N: Skeletal involvement in Langerhans cell histiocytosis. *Insights Imaging* 2013, 4(5):569-579.
- 16.Krooks J, Minkov M, Weatherall AG: Langerhans cell histiocytosis in children: History, classification, pathobiology, clinical manifestations, and prognosis. *J Am Acad Dermatol* 2018, 78(6):1035-1044.
- 17.Abdelaal AHK, Sedky M, Gohar S, Zaki I, Salama A, Hassanain O, El Ghoneimy AM: Skeletal involvement in children with Langerhans cell histiocytosis: healing, complications, and functional outcome. *Sicot j* 2020, 6:28.
- 18.Rodriguez-Galindo C: Clinical features and treatment of Langerhans cell histiocytosis. *Acta Paediatr* 2021, 110(11):2892-2902.
- 19.Grois MMN, Nanduri KMV, Simonitsch-Klupp CR-GI, Weitzman JVS: Histiocyte Society Evaluation and Treatment Guidelines. 2009.
- 20.Kvedaraite E, Lourda M, Han H, Tesi B, Mitchell J, Idestrom M, Mouratidou N, Rassidakis G, von Bahr Greenwood T, Cohen-Aubart F et al: Patients with both Langerhans cell histiocytosis and Crohn's disease highlight a common role of interleukin-23. *Acta Paediatr* 2021, 110(4):1315-1321.
- 21.Imashuku S, Kinugawa N, Matsuzaki A, Kitoh T, Ohki K, Shioda

- Y, Tsunematsu Y, Imamura T, Morimoto A: Langerhans cell histiocytosis with multifocal bone lesions: comparative clinical features between single and multi-systems. *Int J Hematol* 2009, 90(4):506-512.
22. Titgemeyer C, Grois N, Minkov M, Flucher-Wolfram B, Gatterer-Menz I, Gadner H: Pattern and course of single-system disease in Langerhans cell histiocytosis data from the DAL-HX 83- and 90-study. *Med Pediatr Oncol* 2001, 37(2):108-114.
23. Jubran RF, Marachelian A, Dorey F, Malogolowkin M: Predictors of outcome in children with Langerhans cell histiocytosis. *Pediatr Blood Cancer* 2005, 45(1):37-42.
24. Buonocore S, Valente AL, Nightingale D, Bogart J, Souid A-K: Histiocytic Sarcoma in a 3-Year-Old Male: A Case Report. *Pediatrics* 2005, 116(2):e322-e325.
25. Vadivelu S, Mangano FT, Miller CR, Leonard JR: Multifocal Langerhans cell histiocytosis of the pediatric spine: a case report and literature review. *Childs Nerv Syst* 2007, 23(1):127-131.
26. Haupt R, Minkov M, Astigarraga I, Schäfer E, Nanduri V, Jubran R, Egeler RM, Janka G, Micic D, Rodriguez-Galindo C et al: Langerhans cell histiocytosis (LCH): guidelines for diagnosis, clinical work-up, and treatment for patients till the age of 18 years. *Pediatr Blood Cancer* 2013, 60(2):175-184.
27. Hashimoto K, Nishimura S, Sakata N, Inoue M, Sawada A, Akagi M: Treatment Outcomes of Langerhans Cell Histiocytosis: A Retrospective Study. *Medicina (Kaunas)* 2021, 57(4).